

CASE STUDY

Total Fibroid Devascularization With Embozene™ Microspheres

BY LINDALVA BERTELLI FERNANDES, MD

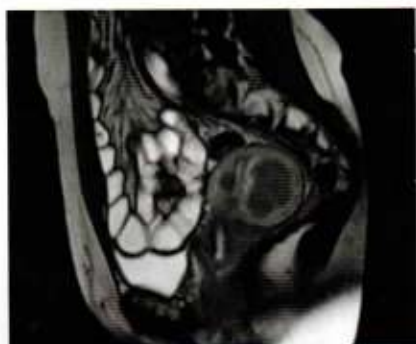

Figure 1. Pre-embolization MRI.

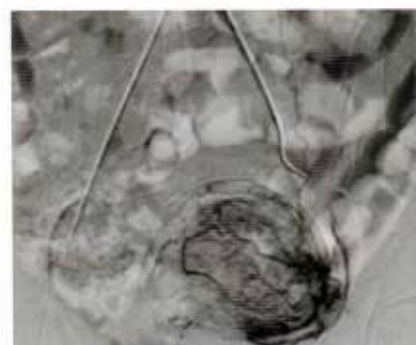


Figure 2. Angiogram of the left uterine artery.

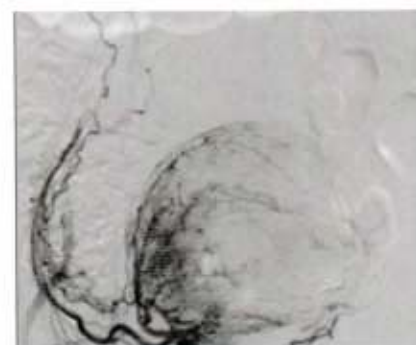


Figure 3. Angiogram of the right uterine artery.

CASE PRESENTATION

A 34-year-old woman presented with pelvic pain, abdominal bloating, and menometrorrhagia (ie, a condition of prolonged bleeding occurring more frequently than normal). She had no prior pregnancy but was seeking treatment from interventional radiology to relieve her symptoms for the possibility of future pregnancy. MRI confirmed the presence of uterine fibroids. Her uterine volume was 134 cm³ (8.1 X 5.8 X 5.5 cm), and she had three fibroids of significant size. The dominant intramural fibroid was 18.9 cm³ (4.0 X 3.5 X 2.6 cm) and extended up to the endometrial cavity, located in the uterine posterior wall. The two smaller fibroids were 1.9 cm³ and 0.9 cm³; one was intramural and the other was submucosal. The fibroids were enhanced after administration of paramagnetic endovenous contrast (**Figure 1**).

PROCEDURE DESCRIPTION

Right femoral access was established by placing a 5-F (1.67-mm) introducer sheath, followed by very selective catheterization of the uterine arteries. First, we accessed the uterine arteries with a selective 5-F (1.67-mm) uterine catheter, and then more distal access was obtained with a 2.7-F (0.9-mm) microcatheter. A pre-embolization selective arteriogram showed uterine-to-ovary anastomosis on both sides (**Figures 2 and 3**). Given this presentation, we chose 900- μ m Embozene™ Microspheres for embolization. We used two vials, each with 2 mL of microspheres, to complete the bilateral embolization. We mixed the microspheres with 7 mL of Ultravist® 300 iodinated contrast (Bayer HealthCare LLC) in a 20-mL syringe, and we injected the microspheres with a 1-mL syringe and three-way stopcock. We performed the embolization by slowly injecting under fluoroscopic guidance. Bilateral embolization was performed to occlude the ascending branches of the uterine arteries leading to the patient's fibroids. Then, after 5 minutes, we performed another arteriogram with a power injection of 8 mL of contrast (Ultravist 300) at a flow rate of 1.5 mL/sec and a frame of 0.5 seconds. This injection showed patency and preservation of the main uterine arteries and cervical branches.

In this case, the efficacy of Embozene™ was demonstrated by the total fibroid devascularization at 4- and 8-month follow-up and by the shrinkage of the dominant fibroid by 96% at 8 months postembolization.

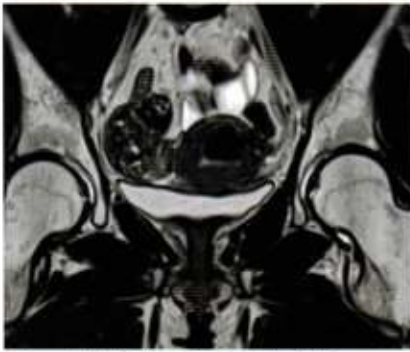


Figure 4. MRI at 4 months postembolization.

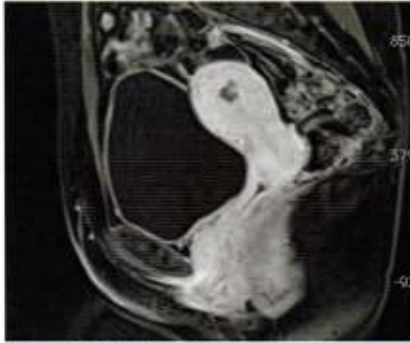

Figure 5. MRI at 8 months postembolization.

FOLLOW-UP AND DISCUSSION

Follow-up imaging was performed at 4 and 8 months postembolization. At 4-month follow-up, the patient reported remission of the menometrorrhagia, and her uterine volume had decreased from 134 cm³ at presentation to 77 cm³, a reduction of 42%. MRI showed total fibroid devascularization of the dominant intramural fibroid and a volume reduction of 73%. Further, there was no evidence of the other fibroids (Figure 4). At 8-month follow-up, the patient reported remission of menometrorrhagia and very good quality of life. Her uterine volume remained unchanged at 77 cm³, but the fibroid volume further reduced to 0.7 cm³, a reduction of 96% from the original 18.9 cm³ (Figure 5). We conclude that uterine artery embolization by using Embozene™ Microspheres is a safe procedure. In our experience, we have never had microcatheter obstruction by using Embozene™ Microspheres. In this case, the efficacy of Embozene™ was demonstrated by the total fibroid devascularization at 4- and 8-month follow-up and by the shrinkage of the dominant fibroid by 96% at 8 months postembolization. The relief of fibroid-related clinical symptoms and better quality of life reported by the patient are further important factors of clinical efficacy.

Lindalva Bertelli Fernandes, MD

Diagnostic and Interventional Radiologist and Neuroradiologist Moinhos

De Vento Hospital, Porto Alegre, Brazil

Member of the Brazilian Society of Interventional Radiological Society of Europe

Disclosures: Received no compensation for this article and is not a consultant to Boston Scientific.

EMBOZENE™ MICROSPHERES

CAUTION: The law restricts these devices to sale by or on the order of a physician. Indications, contraindications, warnings and instructions for use can be found in the product labelling supplied with each device. Information for use only in countries with applicable health authority registrations. Material not intended for use in France.

INDICATIONS FOR USE: Embozene™ Microspheres are indicated for embolization of arteriovenous malformations (A.V.M.) and hypervascular tumors (H.V.T.) including uterine fibroids and hepatoma. **CONTRAINDICATIONS:** The contraindications of Embozene Microspheres include the presence of vasculature where Embozene™ Microspheres could pass directly into the central nervous system, central circulatory system, internal carotid artery, or other non-target territories. Procedures should not be performed if vascular anatomy precludes correct catheter placement or embolic injection. **WARNINGS AND PRECAUTIONS:** Vascular embolization is a high-risk procedure. The procedure should be performed by specialized physicians trained in vascular embolization procedures. Complications can occur at any time during or after the procedure.

CAUTION: Federal (USA) law restricts this device to sale by or on the order of a physician. A complete list of indications, contraindications, warnings and precautions are described in Embozene™ Microspheres Instructions for Use. Please consult these before using the product.

Embozene is a unregistered or registered trademark of Boston Scientific Corporation or its affiliates. All other trademarks are property of their respective owners.

**Boston
Scientific**
Advancing science for life™

Peripheral Interventions

300 Boston Scientific Way
Marlborough, MA 01752-1234
www.bostonscientific.com

To order product or for more information
contact customer service at 1.888.272.1001.

© 2016 Boston Scientific Corporation
or its affiliates. All rights reserved.

PI-379504-AA MAY2016